

Research Article

Studies on Wound Healing Properties of *Quercus infectoria*

SP Umachigi^a, KN Jayaveera^b, CK Ashok Kumar^c, GS Kumar^d,
BM Vrushabendra swamy^e and DV Kishore Kumar^f

^aDepartment of Pharmaceutics, ^dDepartment of Pharmacognosy, ^eDepartment of Pharmacology, ^fDepartment of Chemistry, Rural College of Pharmacy, D.S.Road, Devanahalli-562110 Karnataka, India.

^bDepartment of Chemistry, Jawaharlal Nehru Technological University College of Engineering, Ananthpur- 01, Andhra Pradesh, India.

^cDepartment of Pharmacognosy, Sree Vidyanikethan, College of Pharmacy, A.Rangamepeta, Chittoor Dist, Andhra Pradesh, India.

Abstract

Purpose: The aim of the present study was to investigate the wound healing activity of the selected Indian medicinal plant *Quercus infectoria*.

Method: Ethanol extract of the shade-dried leaves of *Quercus infectoria* was studied for its effect on wound healing in rats, using incision, excision and dead-space wound models, at two different dose levels of 400 and 800 mg/kg.

Result: The plant showed a definite, positive effect on wound healing, with a significant increase in the levels of the antioxidant enzymes, superoxide dismutase and catalase, in the granuloma tissue.

Conclusion: The efficacy of this plant in wound healing may be due to its action on antioxidant enzymes, thereby justifying the traditional claim.

Key words: *Quercus infectoria*, wound healing, superoxide, catalase

*Corresponding Author: E-mail: umachigisanjay@yahoo.co.in

INTRODUCTION

Quercus infectoria Olivier (Fagaceae) is a small tree found in Greece, Asia Minor and Iran. The galls arise on young branches of this tree as a result of attack by the gall-wasp *Adleria gallae-tinctoria*¹ In Asian countries, the galls of *Q. infectoria* have been used for centuries in oriental traditional medicines for treating inflammatory diseases.² Majuphal, a widely known plant in Indian traditional medicine has been used as dental powder and in the treatment of toothache and gingivitis.^{3,4} The galls of *Q. infectoria* have also been pharmacologically documented to possess astringent, antidiabetic,⁵ antitremorine, local anaesthetic,⁶ antiviral,⁷ antibacterial,⁸ antifungal,⁹ larvicidal¹⁰ and anti-inflammatory¹¹ activities. The main constituents found in the galls of *Q. infectoria* are tannin (50-70%) and small amounts of free gallic acid and ellagic acid.¹²⁻¹⁴ We are unable to find any information on the wound-healing properties of this plant.

The present study is therefore an attempt to assess the efficacy of the galls using different parameters of wound healing in rats, and to study the influence of antioxidant enzymes on this property.

MATERIALS AND METHODS

Plant materials

The galls of *Q. infectoria* used in this study were obtained from the local market and were identified based on its physical characteristics. The galls were crushed to small pieces using pestle and mortar and powdered in an electric grinder.

Phytochemical Screening

The powder of the galls of *Quercus infectoria* (50g) was subjected to successive extraction with different solvents in increasing order of polarity from petroleum ether (60°–80°), to benzene, chloroform, acetone, and alcohol, and finally to chloroform: water¹⁵. The dry extracts were subjected to various chemical tests in order to detect the presence of different phytoconstituents¹⁶.

Preparation of Ethanol Extract

The shade-dried, powdered galls (1 kg) were extracted exhaustively using 95% ethanol on a Soxhlet apparatus. The total ethanol extract was concentrated in vacuo to a syrupy consistency (yield 270 g).

Animals

Wistar albino rats of either sex, weighing about 150–250 each, were used for the study. They were fed with standard chow (Pranav Agro Industries Ltd., Sangli, Maharashtra) and water *ad libitum*. They were housed in polypropylene cages maintained under standard conditions (12 hour light - dark cycle; 25 ± 3 °C; 35–60% humidity). The experimental protocol was subjected to the scrutiny of the Institutional Animal Ethics Committee, and was cleared by same before beginning the experiment.

Acute Toxicity Studies

Healthy adult albino rats of either sex, fasted overnight, were divided into 6 groups (n = 6 per cage) and were fed with increasing doses (1, 2, 4, and 8 g/kg body wt.) of the ethanol extract. The total ethanol extract, administered orally in doses of up to 8 g/kg body wt., did not produce any evident sign of toxicity or mortality in rats up to 14 days after administration.

Wound models

The studies were carried out using ether-anesthetized rats and their back was shaved, in three different wound models, at two different dose levels of 400 and 800 mg/kg body wt.

Incision wounds

Two, 6-cm long paravertebral incisions were made through the full thickness of the skin on either side of the vertebral column of the rat¹⁷. Wounds were closed with interrupted sutures, 1 cm apart. The sutures were removed on the seventh day.

Wound-breaking strength was measured in anesthetized rats on the tenth day after wounding¹⁸.

Table 1: Effect of the ethanol extract of *Q. infectoria* on wound healing in the incision and dead-space wound models

Wound Parameter studied	Incision model		Dead space model	
	Breaking Strength (g)	Granuloma Weight (g/100g)	Breaking strength (g)	Hydroxyproline (mg/100g)
Control	221.50 ± 9.07	16.28 ± 1.08	153.83 ± 25.22	972.49 ± 178.38
Ethanol extract of <i>Quercus infectoria</i> 400mg/kg body weight	390.15 ± 13.27 ^a	38.57 ± 2.29 ^a	315.16 ± 23.09 ^a	1542.15 ± 166.28
Ethanol extract of <i>Quercus infectoria</i> 800mg/kg body weight	350.78 ± 19.28 ^a	42.19 ± 7.44 ^a	344.5 ± 23.46 ^a	1884.02 ± 177.59 ^a

^a $P < 0.05$ compared to Control. Values are mean ± S.E.M. (n = 6)

Table 2: Effect of the ethanol extract of *Q. infectoria* on the level of antioxidant enzymes in granuloma tissue

Enzymes	Superoxide dismutase IU/mg	Catalase IU/mg
Control	0.117 ± 0.011	$2.44 \times 10^{-2} \pm 2.6 \times 10^{-3}$
Ethanol extract of <i>Quercus infectoria</i> 400mg/kg body weight	0.178 ± 0.016 ^a	$4.83 \times 10^{-2} \pm 5.7 \times 10^{-3a}$
Ethanol extract of <i>Quercus infectoria</i> 800mg/kg body weight	0.222 ± 0.029 ^a	$6.48 \times 10^{-2} \pm 6.5 \times 10^{-3a}$

^a $P < 0.05$ vs. control. Values are mean ± S.E.M. (n = 6)

Table 3: Effect of the ethanol extract of *Quercus infectoria* on the excision wound model

Wound model	Excision	% of Wound contraction						
		2	4	6	8	10	12	14
Parameters studied	Epithelization Period (days)							
Control	21.33 ± 0.42	14.76 ± 1.58	32.36 ± 1.32	38.38 ± 1.34	46.60 ± 1.2	77.7 ± 2.37	86.65 ± 0.84	91.48 ± 0.54
Ethanol extract of <i>Q. infectoria</i> 400mg/kg body weight	13.66 ± 0.33 ^a	23.76 ± 1.63 ^a	43.34 ± 0.55 ^b	59.66 ± 1.4 ^a	79.14 ± 0.92 ^a	87.79 ± 0.81 ^a	97.02 ± 0.44 ^a	92.21 ± 0.12 ^a
Ethanol extract of <i>Q. infectoria</i> 800mg/kg body weight	14.33 ± 0.84 ^a	25.27 ± 1.41 ^a	31.23 ± 0.75 ^b	54.49 ± 1.1 ^a	72.46 ± 0.12 ^a	91.02 ± 0.81 ^a	95.41 ± 0.47 ^a	98.58 ± 0.42 ^a

^a $P < 0.05$ compared to control; ^b $P < 0.05$ compared to 800 mg. Values are mean ± S.E.M. (n = 6)

Excision wounds

A circular skin piece of full thickness (approximately 500 mm²) was removed from a predetermined dorsal area¹⁹. The wounds were traced on 1- mm² graph paper on the day of wounding and subsequently on alternate days until healing was complete. Changes in the wound area were calculated, giving an indication of the rate of wound contraction. The number of days required for falling of the eschar without any residual raw wound was determined as the period of epithelization.

Dead-space wounds

These wounds were created by implanting two polypropylene tubes (0.5 cm × 2.5 cm each), one on either side, in the lumbar region on the dorsal surface of each rat. On the tenth post-wounding day, the granuloma tissue formed on the implanted tubes was dissected out carefully. Granuloma tissue from one tube was maintained (at -64 °C) for the estimation of antioxidant enzyme levels. The other was used for the determination of tensile strength¹⁹, after which it was dried in an oven at 60 °C for 24 h and the dry weight noted. The acid hydrolysate of the dry tissue was used for the estimation of hydroxyproline content in the tissue²⁰.

Biochemical Attributes

The granuloma tissue from the dead-space model was homogenized in phosphate buffered saline (pH 7.0) and centrifuged under cold conditions. The clear supernatant was assayed spectrophotometrically to determine the levels of the antioxidant enzymes, i.e., superoxide dismutase²¹ and catalase²².

Histopathological studies

A section of the granuloma tissue was subjected to histopathological examination to determine the pattern of lay-down for collagen using two special stains i.e. Van Gieson and Masson Trichrome.

Statistical Analysis

Results, expressed as mean ± SE., were evaluated using one-way ANOVA with post-

hoc Scheffe's *post hoc* test. Values of $p < 0.05$ were considered statistically significant.

RESULTS

Preliminary phytochemical screening revealed the presence of tannins; phenolic compounds. The acute toxicity studies show that the drug was safe up to a maximum dose of 8 g/kg body wt. of the animal.

In the incision wound model, a significant increase was observed in the skin tensile strength of the ethanol extract-treated group on the tenth post-wounding day, at both dose levels (Table 1). The drug-treated animals of the dead-space wound model showed a significant increase in dry granuloma weight, granuloma breaking strength and the level of hydroxyproline content at both dose levels. Histological examination revealed increased collagen deposition in the drug, treated group (Fig. 2), as compared to control (1). Studies on the estimation of antioxidant enzyme reveal that the extract significantly increased the levels of superoxide dismutase and catalase, the two powerful antioxidant enzymes of the body that are known to quench superoxide radicals (Table 2). In studies using the excision wound model, animals treated with the ethanol extract of *Q. infectoria* showed a significant decrease in the epithelization period, as evidenced by the shorter period for the fall of eschar compared to control. The extract also facilitated the rate of wound contraction significantly at both dose levels (Table 3). The results in this study are in support that the wound healing and repair is accelerated by applying *Quercus infectoria* which was high-lighted by the full thickness coverage of the wound area by an organized epidermis in the presence of mature scar tissue in the dermis.

DISCUSSION

Wound healing involves various phases which include granulation, collagenation, collagen maturation and scar maturation²³. Many plant extracts and medicinal herbs have shown potent antioxidant activity. Tannins the main components of many plant extracts, act as free radical scavengers²⁴⁻²⁹. Research into the

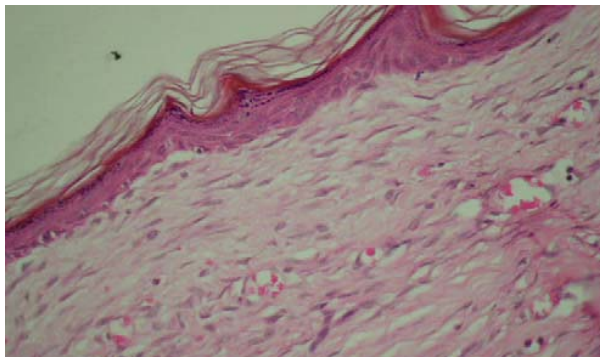


Fig 1: Control (H&E 400x) showing well formed but thick granular cell layer, the underlying dermis contains deposited collagen fibers with minimal inflammation

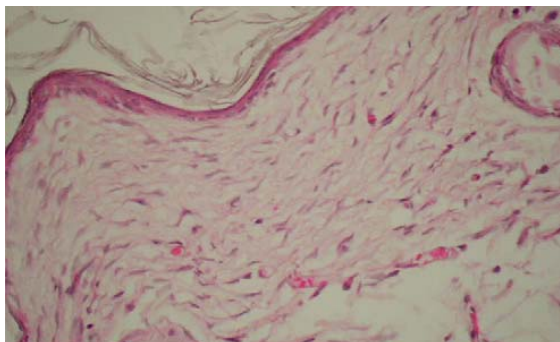


Fig 2: Animals treated with *Quercus infectoria* (H&E 400x) showing thin well-formed epidermis with hair follicle formation in the dermis and no inflammatory cells in a well organized dermis.

role of antioxidants from plant extracts in wound healing has been published widely³⁰. Wound healing process consists of different phases such as granulation, collagenation, collagen maturation and scar maturation which are concurrent but independent to each other. Hence in the present study three different wound models were used. In the incision wound model, a significant increase was observed in the skin tensile strength of the ethanol extract- treated group, at both dose levels (Table 1). The drug-treated animals at both dose levels of the dead-space wound model showed a significant increase in dry granuloma weight, granuloma breaking strength and the level of hydroxyproline content (Table 1). The histopathological study revealed increased collagen deposition in the

drug, treated group (Figs. 1, 2), as compared to control.

Studies on the estimation of antioxidant enzyme revealed that the extract significantly increased the levels of superoxide dismutase and catalase, the two powerful antioxidant enzymes of the body that are known to quench superoxide radicals (Table 2). The antioxidant enzymes (superoxide dismutase and catalase) are known to quench the superoxide radical and thus prevent the damage of cells caused by free radicals. In studies using the excision wound model, animals treated with the ethanol extract of *Q. infectoria* showed a significant decrease in the epithelization period, as evidenced by the shorter period for the fall of eschar compared to control. The drug extract also facilitated the

rate of wound contraction significantly at both dose levels (Table 3).

Phytochemical work reveals that ethanolic extract of galls of *Q. infectoria* contains high amount of tannins, presence of gallic acid, ellagic acid, syringic acid, β -sitosterol and amentoflavone³¹, implied that tannin is one of the active compounds which may be responsible for the antioxidant activity. So in this study scavenging effect might be one of the most important components of wound healing which may be responsible to support wound healing property. Thus the enhanced wound healing may be due to the free radical scavenging action of the plant as well as enhanced antioxidant enzyme level in granuloma tissues.

CONCLUSION

This finding provides an insight into the usage of the galls of *Q. infectoria* in traditional treatment of wounds or burns associated with bacterial infections

REFERENCES

- Samuelsson G. *Drugs of Natural Origin*. 4th Ed. Sweden: Swedish Pharmaceutical Press; Stockholm, 1992. p. 86.
- Anonymous, *The Wealth of India: A Dictionary of Indian Raw Materials and Industrial Products*, 13 volume series. Publications & Information Directorate (CSIR), New Delhi, 1995. p. 351.
- Chopra RN., Nayar SL., Chopra IC., *Glossary of Indian Medicinal Plant*. Council of Scientific and Industrial Research, India, 1956. p. 208.
- Hwang JK, Kong TW, Baek NI, Pyun YR. α -Glycosidase Inhibitory Activity of hexagalloylglucose from the galls of *Quercus infectoria*. *Planta Med* 2000; 66:273-4.
- Dar MS, Ikram M, Fakouhi T. Pharmacology of *Quercus infectoria*. *J Pharm Sci* 1976; 65:1791-4.
- Hussein G, Miyashiro H, Nakamura N, Hattori M, Kakiuchi N, Shimotohno K. Inhibitory effects of Sudanese medicinal plant extracts on hepatitis C virus protease. *Phytother Res* 2000; 14:510-6.
- Fatima S, Farooqi AHA, Kumar R, Kumar TRS, Khanuja SPS. Antibacterial activity possessed by medicinal plants used in tooth powders. *J Med Aromatic Plant Sci* 2001; 22:187-9.
- Digraki M, Alma MH, Ilcim A, Sen S. Antibacterial and antifungal effects of various commercial plant extracts. *Pharm Biol* 1999; 37:216-20.
- Redwane A, Lazrek HB, Bouallam S, Markouk M, Amarouch H, Jana M. Larvicidal activity of extracts from *Quercus lusitania* var. *infectoria* galls (Oliv.). *J Ethnopharmacol* 2002; 79:261-3.
- Kaur G, Hamid H, Ali A, Alam MS, Athar M. Antiinflammatory evaluation of alcoholic extract of galls of *Quercus infectoria*. *J Ethnopharmacol* 2004; 90:285-92.
- Ikram M, Nowshad F. Constituents of *Quercus infectoria*. *Planta Med* 1977; 31: 286-7.
- Dar MS., Ikram M., *Studies on Quercus infectoria; isolation of syringic acid and determination of its central depressive activity*. *Planta Med* 1979; 35: 156-161.
- Wiarat C, Kumar A. *Practical Handbook of Pharmacognosy*. Malaysia: Pearson Education Malaysia Sdn Bhd; 2001.
- Kokate CK *Practical Pharmacognosy*, New Delhi: Vallabh prakashan, 1994. p. 107-111
- Somashekar A Padashetty, Udupa AL Shirwaikar A *Pharmacognostical, Phytochemical and Wound Healing studies of Aristolochia bracteolata lam. (Dissertation)*. Bangalore: Rajiv Gandhi University, Bangalore, India. 2002.
- Kokate CK *Practical Pharmacognosy*, New Delhi, Vallabh Prakashan, 1994. p. 107-111.
- Lee KH *Studies on the mechanism of action of salicylates II. Effects of Vitamin A on Wound Healing retardation action of aspirin*. *J Pharm Sci* 1968; 57: 1238
- Morton JJP, Malone HH *Evaluation of vulnerary activity by open wound procedure in rats*, *Arch Int Pharmacodyn*. 1972; 196: 117
- Neuman RE, Logan MA. The determination of collagen and elastin in tissues. *J Biochem* 1950; 186: 549
- Beauchamp C, Fridovich I *Superoxide dismutase: Improved assays and assay applicable to acrylamide gels*. *Anal Biochem* 1971; 44: 276-287
- Aebi HE In: Bergmeyer H. (eds.), *Methods in Enzymatic Analysis*, Vol 3, 3rd ed, New York, Academic Press, Verlag Chemie, Weinheim, 1973. p.273-286
- Cherry GW, Hughes MA, Kingnorth AN, Arnold FW *Oxford Textbook of Surgery*, Vol I, Morris P. J, Malt R. A (eds), Oxford University Press: Oxford, 1994. p.3-23
- Diwan PV, Tillor LD, Kulkarni DR *Influence of zinc sulphate on steroid depressed healing*. *Ind J Pharmacol* 1979; 11:357
- Bekerecioglu M, Tercan M, Ozyazan I *The effect of Ginkgo biloba (Egb 761) as a free radical scavenger on the survival of skin flaps in rats*. *Scand J Plast Reconstr Hand Surg* 1998; 32: 135-139
- Marja P. Kahkonen, Anu I. Hopia, Heikki J. Vuorela, Jussi-Pekka Rauha, Kalevi Pihlaja Tytti S. Kujala, and Marina Heinonen, *Antioxidant Activity of Plant Extracts Containing Phenolic Compounds*, *J. Agric. Food Chem* 1999; 47: 3954- 3962
- Raquel Pulido, Laura Bravo, and Fulgencio Saura-Calixto, *Antioxidant Activity of Dietary Polyphenols As Determined by a Modified*

- Ferric Reducing/Antioxidant Power Assay*, *J. Agric. Food Chem* 2000; 48:3396-3402
27. Andrea Ghiselli, Mirella Nardini, Alessandro Baldi, and Cristina Scaccini *Antioxidant Activity of Different Phenolic Fractions Separated from an Italian Red Wine*, *J. Agric. Food Chem* 1998; 46: 2.
 28. Tran VH, Hughes MA, Cherry GW. *The effects of polyphenolic extract from Cudrania cochinchinensis on cell response to oxidative damage caused by H₂O₂ and xanthine oxidase*. Abstract 27, First Joint Meeting of Chinese and European Tissue Repair Society, September 22–27, Xi'an, China. 1996
 29. Dutta NK, Shastry MS. *Pharmacological action of A.bracteolata Retz.on the uterus*. *Ind J Pharm* 1959; 20: 302
 30. Hwang JK., Kong TW., Baek NI., Pyun YR *Alpha-glycosidase inhibitory activity of hexagalloylglucose from the galls of Quercus infectoria*. *Planta Med* 2000; 66: 273–274