

Original Research Article

Combined effect of reduced glutathione and ulinastatin on the expressions of IL-6, sIL-6 and sgp130 in peripheral blood of paraquat-poisoned patients

Jianghai Wang¹, Hongting Sun¹, Lihua Fan², Xuepeng Si³, Liang Li¹, Wang Han^{1*}

¹Emergency Department, ²Public Health Section Department, ³Obstetrics Department, Dongying People's Hospital, Dongying, China

*For correspondence: **Email:** wenzhangqinmuhzxhn@163.com

Sent for review: 21 January 2021

Revised accepted: 8 April 2021

Abstract

Purpose: To investigate the effect of reduced glutathione and ulinastatin on the expressions of interleukin-6 (IL-6), soluble interleukin-6 receptor (sIL-6R), and soluble glycoprotein 130 (sgp130) in peripheral blood of paraquat-poisoned patients.

Methods: In this retrospective study, 88 patients with paraquat poisoning admitted to Dongying People's Hospital, Dongying, China from February 2017 to October 2020 were divided into control group (n = 40) and study group (n = 48), based on treatment type. The control group received conventional treatments, while the study group was given reduced glutathione in combination with ulinastatin. Treatment efficacy and peripheral blood expression levels were compared.

Results: Compared to the control group, curative effect was significantly higher in the study group (p < 0.05). The expression levels of IL-6, sIL-6R, and sgp130 in the peripheral blood at the early, middle and late periods in the study group were markedly lower. The number of patients with flake-like or dotted opacity, increased lung texture, pleural effusion and ground glass opacity in the study group during the early period was lower (p < 0.05). Moreover, the number of patients with pulmonary edema, fibrous cord, pleural effusion, ground glass opacity and reticular opacity during the middle period was markedly lower for the study group, while the population of patients with honeycomb lung, fibrous cord, nodules and reticular opacity in the study group was higher (p < 0.05).

Conclusion: A combination of reduced glutathione and ulinastatin produces significant therapeutic effect on paraquat poisoning by down-regulating the serum expressions of IL-6, sIL-6 and sgp130, inhibiting inflammation, and mitigating pulmonary lesions.

Keywords: Reduced glutathione, Ulinastatin, Paraquat poisoning, Interleukin (IL)-6, soluble IL-6 receptor, sgp130

This is an Open Access article that uses a fund-ing model which does not charge readers or their institutions for access and distributed under the terms of the Creative Commons Attribution License (<http://creativecommons.org/licenses/by/4.0>) and the Budapest Open Access Initiative (<http://www.budapestopenaccessinitiative.org/read>), which permit unrestricted use, distribution, and reproduction in any medium, provided the original work is properly credited.

Tropical Journal of Pharmaceutical Research is indexed by Science Citation Index (SciSearch), Scopus, International Pharmaceutical Abstract, Chemical Abstracts, Embase, Index Copernicus, EBSCO, African Index Medicus, JournalSeek, Journal Citation Reports/Science Edition, Directory of Open Access Journals (DOAJ), African Journal Online, Bioline International, Open-J-Gate and Pharmacy Abstracts

INTRODUCTION

Paraquat is a highly effective, low-residue herbicide that does not pollute the soil. It is widely used in China, but it is highly toxic to

humans and animals. Currently, acute paraquat poisoning, a major type of pesticide poisoning in the emergency departments of hospitals in some regions, is mostly due to oral poisoning, and it is of rapid onset, resulting in extremely high fatality

rate and poor prognosis [1,2]. So far, a unified standard or guideline has not yet been adopted for the treatment of paraquat poisoning in China and elsewhere. The frequently-employed symptomatic treatments involve gastric lavage, scavenging of oxygen free radicals, and blood purification, but these strategies have not reduced the high mortality rate associated with paraquat poisoning [3,4]. Reduced glutathione is a tripeptide with good anti-inflammatory, antioxidant and microcirculation-enhancing properties [5,6].

Ulinastatin is often used clinically to treat patients with acute circulatory failure. It mitigates hypoxia and reduces lung damage. In addition, it mimics glucocorticoid function and inhibits the release of proinflammatory factors [7,8]. At present, the specific mechanism involved in paraquat poisoning is unclear, leading to treatment difficulties. In recent years, scholars have discovered that the IL-6/STAT3 signaling pathway plays a critical part in paraquat poisoning, and this has led to increased interest in research on paraquat toxicity [9,10]. This study retrospectively analyzed the clinical data of 88 paraquat-poisoned patients admitted to our hospital from February 2017 to October 2020, with the aim of investigating the effect of combination treatment using reduced glutathione and ulinastatin on the expressions of IL-6, sIL-6R and sgp130.

METHODS

Patients

Eighty-eight (88) patients with paraquat poisoning admitted to our hospital over a period of February 2017 to October 2020 were assigned into control group (n = 40) and study group (n = 48), based on their treatments. The former group received conventional treatment, while the latter group was given combination of reduced glutathione and ulinastatin. The two groups were comparable in general data ($p > 0.05$, Table 1).

Treatments

The control group received conventional treatment, and was given 30% montmorillonite

solution in water for gastric lavage, followed by continuation of intake of montmorillonite powder. Mannitol (20%) was given for catharsis, until disappearance of dark green color in the stool. The patients also received blood perfusion (4 h at a time) for 3 consecutive days, as well as vitamin B, vitamin C and ligustrazine. Methylprednisolone (500 mg) was dissolved in 100 ml of normal saline and administered twice a day in the form of intravenous drip. Respiratory support and tracheal intubation were carried out when necessary.

For patients in the study group, 1.2 g of reduced glutathione (Shanghai Fudan Forward Pharmaceutical Company Ltd (NMPA approval number: H20031265; specification: 0.6 g) was added to 250 mL of 5 % glucose solution, and given as intravenous drip, once a day, for 7 consecutive days. Moreover, 200,000 units of Ulinastatin (Techpool Bio-Pharma Co. Ltd (NMPA approval number: H19990133; specification: 50000 units) were added to 250 mL of 5 % glucose solution and administered intravenously, twice a day for 7 consecutive days.

Measurement of indicators

The criteria for evaluation of treatment efficacy are shown in Table 2. Total treatment effectiveness was calculated using Eq 1.

$$A (\%) = \{(B + C)/D\}100 \dots\dots\dots (1)$$

A: total effectiveness; B: number of cured cases; C: number of improved cases; D: total number of cases.

The levels of IL-6, sIL-6R, and sgp130 in the peripheral blood of patients were determined when the patients were admitted to the hospital, at 5 days of treatment, and after treatment. Peripheral blood (5 mL) was centrifuged at 3500 rpm for 10 min, and the supernatant was preserved in a cold storage at -80 °C. Enzyme-linked immunosorbent assay was used to measure the levels of IL-6, sIL-6R, and sgp130 in peripheral blood, using their respective assay kits (Shanghai H Yinyuan Biological Technology Co. Ltd) in line with the manufacturers' instructions.

Table 1: Patient profile

Group	n	Sex		Age	Clinic time (h)	Dosage (mL)
		Male	Female			
Control	40	14 (35.0)	26 (65.0)	32.40±7.10	5.40±1.60	45.14±10.04
Study	48	20 (41.67)	28 (58.33)	31.22±6.08	6.02±1.72	48.01±10.36
t/X ² -value		0.409		0.84	1.738	1.312
P-value		0.522		0.403	0.086	0.193

Table 2: Criteria used for evaluation of treatment effectiveness

Efficacy	Evaluation criterion
Cured	Clinical symptoms disappeared and the chest CT showed no obvious abnormalities
Improved	Only mild respiratory symptoms; blood biochemical indicators and blood oxygen saturation are basically normal, chest CT shows lung interstitial changes
Ineffective	Death

Table 3: Comparison of treatment effectiveness ups {n (%)}

Group	N	Cured	Improved	Invalid	Total effectiveness
Control	40	5 (12.50)	12 (30.0)	23 (57.50)	17 (42.50)
Study	48	14 (29.17)	16 (33.33)	18 (37.50)	30 (62.50)
χ^2				2.137	
P-value				0.033	

Lung damage was assessed with chest CT examinations at the time of admission, and every 3 to 5 days after admission. Changes in CT results at the early period (within 5 days of treatment), middle period (7 - 14 days post-admission) and late period (after treatment) were compared between the two groups.

Statistical analysis

In this study, SPSS 21.0 was employed to process and analyze the data obtained. Quantitative data were expressed as mean \pm standard deviation (SD), and investigated with *t*-test. Qualitative data were presented as percentage (%), and performed with chi-square or rank-sum test. $P < 0.05$ was assumed to indicate statistical differences.

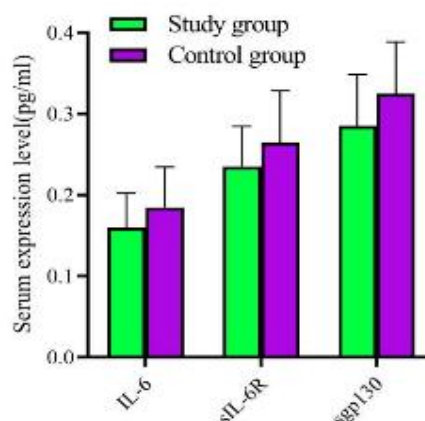
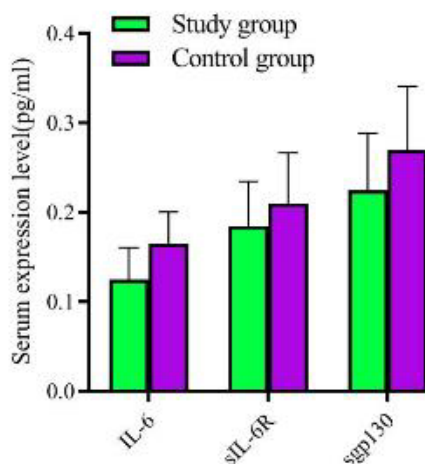
RESULTS

Treatment efficacy

As shown in Table 3, study group witnessed higher treatment effectiveness than the control group ($p < 0.05$).

Peripheral blood levels of IL-6, sIL-6R and sgp130

The levels of IL-6, sIL-6R and sgp130 in peripheral blood of the study group were significantly lower than those in the control group in the early period (within 5 days after treatment), middle period (7 - 14 days of treatment), and later period (after treatment) ($p < 0.05$). See Figure 1, Figure 2 and Figure 3.

**Figure 1:** Peripheral blood levels of IL-6, sIL-6R and sgp130 in the early period**Figure 2:** Peripheral blood levels of IL-6, sIL-6R and sgp130 in the middle period

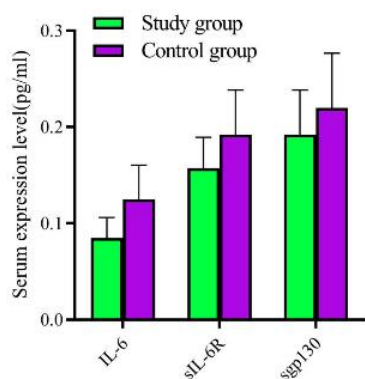


Figure 3: Peripheral blood levels of IL-6, sIL-6R and sgp130 in the later period

Lung CT

There was a lower number of patients with flake-like or dotted opacity, increased lung texture, pleural effusion and ground glass opacity in the study group during the early period (within 5 days after treatment) than in the control group. In addition, lower number of patients had pulmonary edema, fibrous cord, pleural effusion, ground glass opacity and reticular opacity in the study group during the middle period (7 - 14 days) than in the control group. The number of patients with honeycomb lungs, fibrous cord, nodules and reticular opacity was lower in the

study group than in the control group ($p < 0.05$). See Table 4, Table 5 and Table 6.

DISCUSSION

Oxidative damage and inflammation are generally considered as important mechanisms through which paraquat poisoning causes lung damage. Free radicals cause oxidative damage, induce secretion of specific chemokines, stimulate alveolar tissue cells to release a variety of cytokines such as TNF- α and IL-6 [11], initiate inflammatory cascade, trigger the "cascade effect", and cause severe inflammatory damage to the lungs [12]. Interleukin-6 (IL-6) participates in the cytokine network. It induces the homodimerization of gp130 by binding to its receptor, and activates the downstream JAK-STAT3 pathway, thereby stimulating the expression of IL-6-targeted response genes. It has been reported that IL-6 is of great importance in cell proliferation and differentiation, angiogenesis, and inflammation [13]. It exists in two forms: sIL-6 and mL-6. In the healthy state, the amount of sIL-6 is usually low. Most sIL-6s are formed by the "shedding" of mL-6 through the action of related proteases. IL-6 binds to sIL-6 and sIL-6R, and inhibits the release of mL-6R from endothelial cells and smooth muscle cells.

Table 4: Comparison of lung CT in the early period between the two groups {n (%)}

Group	Cases (n)	Flake-like or dotted opacity	Increased lung texture	Pleural effusion	Ground glass opacity
Control	40	27 (67.50)	28 (70.0)	17 (42.50)	20 (50.0)
Study	48	20 (41.67)	19 (39.58)	10 (20.83)	12 (25.0)
χ^2		5.851	8.112	4.816	5.893
P-value		0.016	0.004	0.028	0.015

Table 5: Comparison of lung CT in the middle period {n (%)}

Group	Cases (n)	Pulmonary edema	Fibrous cord	Pleural effusion	Ground glass opacity	Reticular opacity
Control	40	18 (45.0)	24 (60.0)	19 (47.50)	24 (60.0)	13 (32.50)
Study	48	9 (18.75)	13 (27.08)	7 (14.58)	14 (29.17)	4 (8.33)
χ^2		7.069	9.702	11.357	8.454	8.175
P-value		0.008	0.002	0.001	0.004	0.004

Table 6: Comparison of lung CT in the late period {n (%)}

Group	Cases (n)	Honeycomb lungs	Fibrous cord	Nodules opacity	Reticular opacity
Control	40	17 (42.50)	19 (47.50)	24 (60.0)	24 (60.0)
Study	48	5 (10.42)	11 (22.92)	12 (25.0)	14 (29.17)
χ^2		11.978	5.868	11.056	8.454
P-value		0.001	0.015	0.001	0.004

This is called the trans-signaling pathway of IL-6, and it has a pro-inflammatory effect. In the serum of patients with multiple organ dysfunction syndrome, the levels of sIL-6R and sgp130 increase along with rise in IL-6 level as the disease worsens, thereby aggravating inflammatory responses [14].

Paraquat brings about lung damage through a characteristic process. At the early and mid-stages of poisoning, inflammatory cell infiltration in the lungs promotes the release of a large amount of oxidized substances, leading to aggravation of lung damage, pulmonary edema and hemorrhage. As the disease worsens, pulmonary interstitial fibrosis appears at the late stage [15]. At present, there are no specific drugs for treating paraquat poisoning. The most frequently used clinical method for saving patients is blood purification. However, paraquat has a strong affinity for the lungs, thereby limiting the effectiveness of blood purification [16]. Ulinastatin exerts potent inhibitory effects on a variety of enzymes. It belongs to an important class of bioactive substances that regulate cell expression and secretion. It effectively regulates inflammatory response, inhibits inflammation, protects body tissues, promotes tissue repair, and reduces inflammatory damage [17]. Reduced glutathione is the biologically active form of glutathione. It enhances the metabolism of carbohydrates, lipids and proteins, and participates actively in the neutralization of free radicals, thereby maintaining the stability of the internal environment [18].

Studies have shown that organophosphorus pesticide poisoning lowers reduced glutathione levels. Appropriate supplementation with exogenous reduced glutathione effectively reduces tissue cell damage. Due to its strong antioxidant and anti-inflammatory properties, reduced glutathione protects the liver, kidney, lung and other organs from ROS-induced damage [15]. Therefore, reduced glutathione is often used clinically for the treatment of acute and critical illnesses. In this study, the study group obtained more excellent treatment efficacy. Moreover, the study group observed remarkably lower levels of IL-6, sIL-6R and sgp130 in the peripheral blood in the early, middle and late periods. Also, the study group exhibited more favorable lung CT at each of the stages studied. These results indicate that the use of reduced glutathione and ulinastatin produces a significant and beneficial effect on patients with paraquat poisoning. The combined treatment effectively down-regulated the serum expressions of IL-6, sIL-6 and sgp130, inhibited inflammation, and reduced lung damage.

Limitations of this study

The sample size used in this study was small. Moreover, the results may be biased, since the study was a retrospective analysis. Therefore, there is need to use a larger sample size and conduct a prospective study so as to validate the findings obtained in the present investigation.

CONCLUSION

Combination of reduced glutathione and ulinastatin produces a significant and beneficial outcome in the treatment of paraquat poisoning by effectively down-regulating the serum expressions of IL-6, sIL-6 and sgp130; inhibiting inflammatory response and reducing pulmonary lesions.

DECLARATIONS

Acknowledgement

The authors thank all staff in Emergency Department of Dongying People's Hospital for their assistance for this study.

Conflict of interest

No conflict of interest is associated with this work.

Contribution of authors

We declare that this work was done by the authors named in this article and all liabilities pertaining to claims relating to the content of this article will be borne by the authors.

Open Access

This is an Open Access article that uses a funding model which does not charge readers or their institutions for access and distributed under the terms of the Creative Commons Attribution License (<http://creativecommons.org/licenses/by/4.0>) and the Budapest Open Access Initiative (<http://www.budapestopenaccessinitiative.org/read>), which permit unrestricted use, distribution, and reproduction in any medium, provided the original work is properly credited.

REFERENCES

1. Wan X, Li X, Wang Q, Zheng B, Zhou C, Kang X, Hu D, Bao H, Peng A. Metabolic profiling of amino acids in paraquat-induced acute kidney injury. *Clin Exp Nephrol*. 2019; 23:474-483.

2. Gawarammana I, Buckley NA, Mohamed F, Naser K, Jeganathan K, Ariyananada PL, Wunnapak K, Dobbins TA, Tomenson JA, Wilks MF, Eddleston M, Dawson AH. High-dose immunosuppression to prevent death after paraquat self-poisoning - a randomised controlled trial. *Clin Toxicol (Phila)*. 2018; 56:633-639.
3. Zyoud SH. Investigating global trends in paraquat intoxication research from 1962 to 2015 using bibliometric analysis. *Am J Ind Med*. 2018; 61:462-470.
4. Li C, Hu D, Xue W, Li X, Wang Z, Ai Z, Song Y, Liu X, Cheng J, Fan S, Zhao L, Wang L, Mohan C, Peng A. Treatment Outcome of Combined Continuous Venovenous Hemofiltration and Hemoperfusion in Acute Paraquat Poisoning: A Prospective Controlled Trial. *Crit Care Med*. 2018; 46:100-107.
5. Giustarini D, Colombo G, Garavaglia ML, Astori E, Portinaro NM, Reggiani F, Badalamenti S, Aloisi AM, Santucci A, Rossi R, Milzani A, Dalle-Donne I. Assessment of glutathione/glutathione disulphide ratio and S-glutathionylated proteins in human blood, solid tissues, and cultured cells. *Free Radic Biol Med*. 2017; 112:360-375.
6. Hou Y, Li X, Dai Z, Wu Z, Bazer FW, Wu G. Analysis of Glutathione in Biological Samples by HPLC Involving Pre-Column Derivatization with o-Phthalaldehyde. *Methods Mol Biol*. 2018; 1694:105-115.
7. Deng P, Chen Y, Li H, Wan Z. Pneumomediastinum caused by occult paraquat poisoning: Case report. *Medicine (Baltimore)*. 2018; 97:e13745.
8. Shi X, Zhang Y, Wang Y. Impact of Xuebijing and ulinastatin as assistance for hemoperfusion in treating acute paraquat poisoning. *Int J Clin Exp Med*. 2015; 8:14018-23.
9. Fang XZ, Huang TF, Wang CJ, Ge YL, Lin SY, Zhang Y, Gao J. Preconditioning of physiological cyclic stretch attenuated HMGB1 expression in pathologically mechanical stretch-activated A549 cells and ventilator-induced lung injury rats through inhibition of IL-6/STAT3/SOCS3. *Int Immunopharmacol*. 2016; 31:66-73.
10. Palma DA, Senan S, Tsujino K, Barriger RB, Rengan R, Moreno M, Bradley JD, Kim TH, Ramella S, Marks LB, De Petris L, Stitt L, Rodrigues G. Predicting radiation pneumonitis after chemoradiation therapy for lung cancer: an international individual patient data meta-analysis. *Int J Radiat Oncol Biol Phys*. 2013; 85:444-50.
11. Huang J, Ning N, Zhang W. Effects of paraquat on IL-6 and TNF- α in macrophages. *Exp Ther Med*. 2019; 17:1783-1789.
12. Shen H, Wu N, Wang Y, Han X, Zheng Q, Cai X, Zhang H, Zhao M. JNK Inhibitor SP600125 Attenuates Paraquat-Induced Acute Lung Injury: an In Vivo and In Vitro Study. *Inflammation*. 2017; 40:1319-1330.
13. Heo TH, Wahler J, Suh N. Potential therapeutic implications of IL-6/IL-6R/gp130-targeting agents in breast cancer. *Oncotarget*. 2016; 7:15460-73.
14. Zegeye MM, Lindkvist M, Fälker K, Kumawat AK, Paramel G, Grenegård M, Sirsjö A, Ljungberg LU. Activation of the JAK/STAT3 and PI3K/AKT pathways are crucial for IL-6 trans-signaling-mediated pro-inflammatory response in human vascular endothelial cells. *Cell Commun Signal*. 2018 5; 16:55.
15. Kanchan T, Bakkannavar SM, Acharya PR. Paraquat Poisoning: Analysis of an Uncommon Cause of Fatal Poisoning from Manipal, South India. *Toxicol Int*. 2015; 22:30-4.
16. Sun L, Yan PB, Zhang Y, Wei LQ, Li GQ. Effect of activated charcoal hemoperfusion on renal function in patients with paraquat poisoning. *Exp Ther Med*. 2018; 15:2688-2692.
17. Li HF, Zhao SX, Xing BP, Sun ML. Ulinastatin suppresses endoplasmic reticulum stress and apoptosis in the hippocampus of rats with acute paraquat poisoning. *Neural Regen Res*. 2015; 10:467-72.
18. Li GQ, Li YM, Wei LQ, Liu Y, Zhang YH. Comparison between kidney and continuous plasma perfusion for paraquat elimination. *Am J Med Sci*. 2014; 348: 195-203.