

## Original Research Article

# Inhibitory effect of PD173074 drug on DMBA-induced mammary carcinoma in female Swiss albino mice

Abeer S Alghamdi, Hussah M Alobaid, Ahmed M Rady, Badr Abdullah Aldahmash, Wejdan S AL-Qahtani, Aisha H Alqarni, Samiah A Almalki, Doaa M Elnagar\*

College of Science, Department of Zoology, King Saud University P.O. Box 2455, Riyadh 11451, Saudi Arabia

\*For correspondence: **Email:** [elnagard1@yahoo.com](mailto:elnagard1@yahoo.com); **Tel:** +966-554425428

Sent for review: 3 September 2024

Revised accepted: 9 December 2024

## Abstract

**Purpose:** To determine the effect of PD173074 on mammary carcinoma.

**Methods:** Virgin female mice were randomly divided into 4 groups of 10 mice per group. Group 1 (control) received clean water, group 2 received an oral dose of 50 mg/kg PD173074 twice a week, group 3 received a single dose of 50 mg/kg 7,12-Dimethylbenz(a)anthracene (DMBA) in the breast for carcinoma induction, group 4 received DMBA and after that treated with PD173074 one week later for 4 weeks. Hormonal analysis, oxidative stress, levels of cytokines IL6 and TNF- $\alpha$ , and histopathological and immunohistochemical analysis were carried out.

**Results:** Treatment with PD173074 significantly lowered estrogen, progesterone, oxidative stress indices, cytokines IL6, and TNF- $\alpha$  levels ( $p < 0.05$ ) raised due to carcinoma induction. Pyrido (2,3-d) pyrimidine derivative PD173074 lowered the Nottingham histopathological score and reduced the incidence of invasive ductal carcinoma. Furthermore, immunohistochemical analysis showed that post-treatment with PD173074 significantly decreased K167 expression ( $p < 0.05$ ).

**Conclusion:** PD173074 significantly reduces estrogen, progesterone, oxidative stress indices, cytokines, TNF- $\alpha$ , Nottingham histopathological score, and KI-67 expression. Additional studies would be required to validate the actual mechanisms of this drug action.

**Keywords:** PD173074 drug, Mammary carcinoma, 7,12-Dimethylbenz(a)anthracene (DMBA), Nottingham histopathological score

This is an Open Access article that uses a funding model which does not charge readers or their institutions for access and distributed under the terms of the Creative Commons Attribution License (<http://creativecommons.org/licenses/by/4.0>) and the Budapest Open Access Initiative (<http://www.budapestopenaccessinitiative.org/read>), which permit unrestricted use, distribution, and reproduction in any medium, provided the original work is properly credited.

Tropical Journal of Pharmaceutical Research is indexed by Scopus, Chemical Abstracts, Embase, Index Copernicus, EBSCO, African Index Medicus, JournalSeek, Directory of Open Access Journals (DOAJ), African Journal Online, Bioline International, Open-J-Gate and Pharmacy Abstracts

## INTRODUCTION

In women, breast cancer remains the leading cause of cancer-related mortality due to its extensive heterogeneity, metastasis, and resistance to treatment [1]. The death rate for breast cancer for women aged 30 to 79 was 48.3 deaths per 100,000 women in 1975. However, by 2000, the rate had reduced to 38 deaths per

100,000 women. Average yearly percentage change for breast cancer-related fatalities dropped by 2.9 % in 2010, and this trend is predicted to continue beyond 2030. Breast cancer pathology is determined by some general factors such as family history, lifestyle, nutrition and use of alcohol or drugs [2]. Majority of early breast cancer tumors showed positivity for hormone receptors (HR) like estrogen (ER+) or

progesterone (PR+), accounting for 60-70 % of cases. Additionally, some instances revealed positivity to human epidermal growth factor type 2 receptor (HER2). Generally, (ER+) tumors have shown more response to anti-hormonal treatment [3]. There are two types of ER; ER $\alpha$  and ER $\beta$ . There are also two different types of progesterone receptors; PRA and PRB. The function of estrogen is modulated by progesterone. It has been found that ER-positive breast tumors with no PR expression showed less response to hormone therapy compared to those with PR expression. It is also evident that the phenotypes of ER and PR are not constant. These may alter the course of the disease's natural course or the result of therapy [4].

Primary breast cancer has traditionally been treated with a combination of hormone therapy, cytotoxic chemotherapy, radiation, surgery (lumpectomy, partial or total mastectomy), and most recently, immunotherapy (e.g., trastuzumab). Breast tumors are often classified into four phases based on their size, location, and signs of metastasis [5]. On the other hand, side effects of chemotherapy and radiotherapy also may participate in breast cancer induction [1]. Breast cancer's first stage is characterized by ductal hyperproliferation. It then develops according to many factors, and the profile genome is the primary factor that may turn the benign tumor into a malignant one [4].

Some tumors showed significant resistance against drugs, which is considered a serious threat to cancer therapy [5]. For this reason, finding novel compounds that have a therapeutic impact on mammary adenocarcinoma is required. Novel compounds target the fibroblast growth factor (FGFR) family such as tyrosine kinase inhibitor (TKI) which is implicated in mammary carcinoma [6]. PD173074 is a likely selective inhibitor of FGFR. Therefore, many studies have tested the compound on breast cancer cells *in vitro*, in which it decreases cell viability, and increases apoptosis and the ratio of Bax/Bcl-2. Also, the decrease in FGFR by PD173074 led to a reduction in myeloid-derived suppressor cells in the tumor, blood and spleens of the animals, which is associated with CD4 and CD8 T cells increase [7]. Therefore, this study investigated the effect of PD173074 on mammary carcinoma induced by 7,12-Dimethylbenz(a)anthracene DMBA.

## EXPERIMENTAL

### Animals

Forty virgin Swiss albino females, weighed  $25 \pm 5$  g aged 14 weeks were obtained from the animal house of the College of Science, King Saud University, Riyadh, Saudi Arabia. Animals were kept in clean cages under normal environmental conditions (25 °C, 12 h light-dark cycle, and free access to balanced food and clean water).

Ethical approval was obtained from the Institutional Review Board (IRB), King Saud University, Riyadh, Saudi Arabia (Ethics reference No. KSU-SE-21-67) and complied with the internationally accepted guideline for the use and care of laboratory animals, published by the US National Institutes of Health [8].

### Design and sample collection

Animals were randomly divided into 4 groups of 10 mice per each. Group 1 served as control, group 2 received oral dose of 50 mg/kg PD173074 (APEXBIO-China) twice a week, group 3 received a single dose of 50 mg/kg DMBA (Sigma-Germany) in the breast fat pad, group 4 received DMBA as group 3, and treated one week later with PD173074 as in group 2. Duration of treatment with PD173074 was 4 weeks. At end of the study, animals were sacrificed under anesthesia by carbon dioxide (CO<sub>2</sub>) flow. Blood samples were collected from the heart, and centrifuged at x3000 g for 30 min. Serum was collected and stored at -20 °C till assay. Breast pieces from all groups were collected and fixed in 10 % formalin. The liver was collected and homogenized in phosphate buffer saline (PBS) 1:5 on ice for 3 min, then centrifuged twice at x3000 g for 20 min. The supernatant was filtered and stored at -20 °C till further assay.

### Biochemical analysis

#### Estimation of female hormones

Estrogen and progesterone hormones were evaluated in serum by enzyme-linked immunosorbent assay (ELISA) using its commercial kits according to the manufacturer's protocol.

#### Determination of oxidative stress

Malondialdehyde (MDA) and glutathione reductase (GSH) were determined in liver

homogenate using commercial kits and spectrophotometry.

### Evaluation of inflammatory cytokines

Interleukin-6 (IL6), tumor necrosis factor-alpha (TNF- $\alpha$ ), and inflammatory cytokines were evaluated using ELISA.

### Histopathological analysis

Breast samples were collected and fixed in 10 % formalin. Then, samples were dehydrated in ascending grades of alcohol. Samples were embedded in paraffin wax, then sectioned at 6  $\mu$ m and dried. Sections were stained by hematoxylin and eosin, and counter-stained by Masson's trichrome. Sections were classified according to Nottingham histopathological score [9] as follows: grade 0 (1-2), grade I (3-5), and grade II scores.

### Immunohistochemistry

The KI-67 cells in breast tissue were detected using Avidin Biotin Complex method (ABC). Sections were deparaffinized and rehydrated, then unmasked using citrate buffer in a microwave for 5 min. Sections were washed with PBS buffer 3 times, then incubated with hydrogen peroxide blocking solution followed by protein block after washing. Samples were incubated with primary antibody.

### Statistical analysis

Data was analyzed using Statistical Packages for Social Sciences version 16.0 (SPSS, IBM, Armonk, NY, USA). Data was expressed as mean  $\pm$  standard error of the mean (SEM) and analyzed using analysis of variance (ANOVA) one-way test.  $P < 0.05$  was considered significant.

## RESULTS

### PD173074 inhibited levels of estrogen and progesterone

Estrogen levels did not change significantly in all groups compared to control group. However, treatment with PD173074 alone increased progesterone levels compared to control group. Treatment with DMBA significantly increased progesterone levels ( $p < 0.05$ ) compared to control group. Furthermore, treatment with PD173074 after DMBA significantly decreased progesterone level ( $p < 0.05$ ) compared to DMBA (Table 1).

### PD173074 significantly reduced oxidative stress raised by DMBA

Treatment with PD173074 alone, and DMBA significantly increased MDA, and decreased GSH compared to control group ( $p < 0.05$ ). However, after treatment with PD173074 following DMBA induction, levels of MDA significantly decreased while GSH increased compared to DMBA alone (Table 2).

**Table 1:** PD173074 decreased progesterone levels increased by DMBA

Group	Estrogen (pg/mL)	Progesterone (pg/mL)
Control	3.8 $\pm$ 1.17	1.6 $\pm$ 0.02
PD173074	4 $\pm$ 0.1	2.1 $\pm$ 0.02
DMBA	4.5 $\pm$ 0.33	5.4 $\pm$ 0.23 <sup>a</sup>
DMBA+PD	4.2 $\pm$ 0.18	2.7 $\pm$ 0.05 <sup>ab</sup>
Mean $\pm$ SEM, $p \leq 0.05$ , <sup>a</sup> $p < 0.05$ vs control, <sup>b</sup> $p < 0.05$ vs DMBA		

**Table 2:** The effect of PD173074 on MDA and GSH levels

Group	MDA (nmol/g)	GSH (nmol/g)
Control	19.8 $\pm$ 0.28	454 $\pm$ 50.5
PD173074	47.5 $\pm$ 4.5 <sup>a</sup>	364 $\pm$ 0 <sup>a</sup>
DMBA	93.6 $\pm$ 2.5 <sup>a</sup>	149 $\pm$ 6.1 <sup>a</sup>
DMBA+PD	87.4 $\pm$ 0.94 <sup>a</sup>	373.4 $\pm$ 0 <sup>ab</sup>
Mean $\pm$ SEM, <sup>a</sup> $p < 0.05$ vs control group, <sup>b</sup> $p < 0.05$ vs DMBA group		

### PD173074 lowered inflammatory cytokines

There was no significant increase in cytokine levels (IL6 & TNF  $\alpha$ ) following treatment with PD173074 compared to control group. Furthermore, induction with DMBA resulted in significantly higher levels of IL6, and TNF- $\alpha$  ( $p < 0.05$ ) compared to control. Also, treatment with PD173074 following DMBA induction resulted in significantly lower levels of IL6 and TNF- $\alpha$  ( $p < 0.05$ ) compared to DMBA alone.

### PD173074 reduced the incidence of invasive tubular mammary adenocarcinoma

Breast tissue from control group showed normal appearance with mammary glands and ducts which penetrated the adipose tissue (Figure 1 A and Figure 2 A). Also, the mice group treated with PD173074 revealed congested breast tissue (Figure 1 B) with depositions of fibers around glands and ducts (Figure 2 B). However, treatment with a single dose of DMBA only in the breast fat pad displayed a heavy incidence of invasive tubular mammary adenocarcinoma with atypical pleomorphic cancer cells and formed carcinoma nests (Figure 1 C) in desmoplastic stroma stained blue with Masson's trichrome

(Figure 2 C; adenocarcinoma classified as grade II scored 7 according to Nottingham histopathological score). Following treatment with PD173074 after tumor induction by DMBA showed less incidence of carcinoma (Figure 1 D), but with the presence of desmoplastic stroma surrounding ducts (Figure 2 D; classified as grade I scored 5 according to Nottingham histopathological score; Table 4).

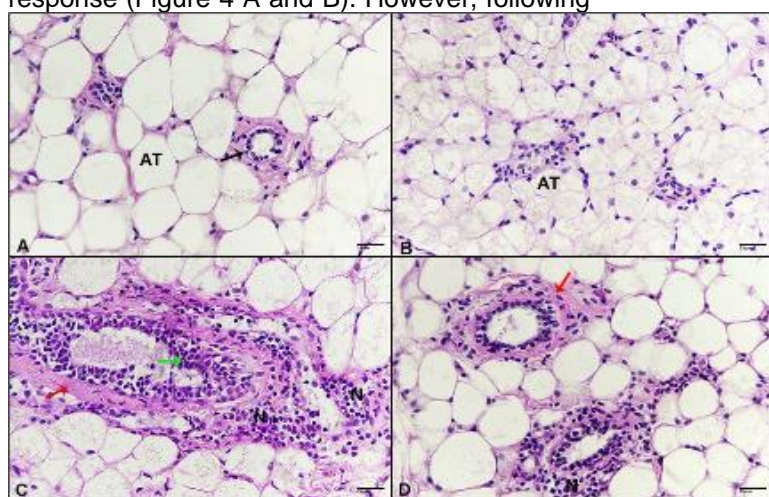
#### PD173074 inhibited *KI-67* gene expression in invasive mammary carcinoma

Breast tissues of control group mice and mice treated with PD173074 revealed weak immune response (Figure 4 A and B). However, following

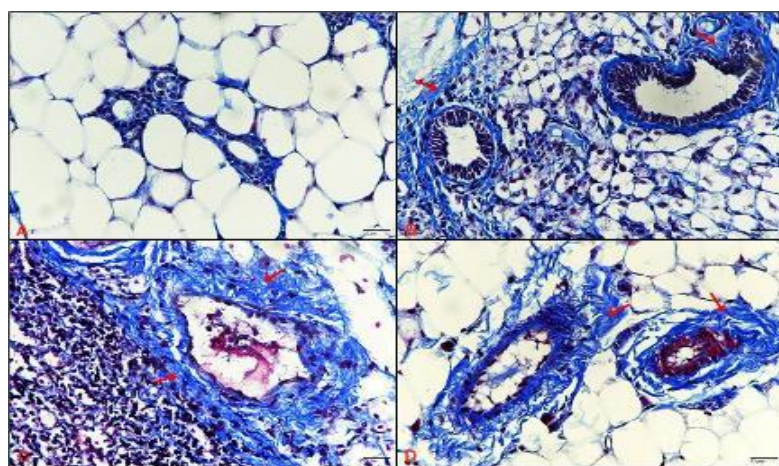
induction with a single dose of DMBA exhibited a strong immune response (Figure 4 C) with high tumor cell count and high percentage of KI-67 presence ( $p < 0.05$ ; Table 5).

**Table 4:** Nottingham histopathological score showing reducing effect of PD173074 on mammary adenocarcinoma

Group	Grade	Score
Control	0	0
PD173074	0	0
DMBA	II	7
DMBA+PD	I	5



**Figure 1:** Photomicrographs of breast tissue (A) untreated control showing normal appearance, adipose tissue (AT), gland (black arrow), (B) breast of mice treated with 50 mg/kg of PD173074 displaying congested tissue, (C) breast of mice treated with a single dose (50 mg/kg) of DMBA revealing invasive tubular adenocarcinoma, atypical proliferative cells in the ductal lumen (green arrow), carcinoma nests (N), desmoplastic stroma (red arrow), (D) breast of mice treated with 50 mg/kg of PD173074 after tumor induction showing less carcinoma incidence (H & E – 400 X)



**Figure 2:** Photomicrographs of breast tissue (A) untreated control showing no fibrosis, (B) breast of mice treated with 50 mg/kg of PD173074 displaying depositions of collagenous fibers around glands and tubules, (C) breast of mice treated with single dose (50 mg/kg) of DMBA revealing intense desmoplastic stroma (red arrow), (D) breast of mice treated with 50 mg/kg of PD173074 after tumor induction showing intense desmoplastic reaction (M.tr.-400x)

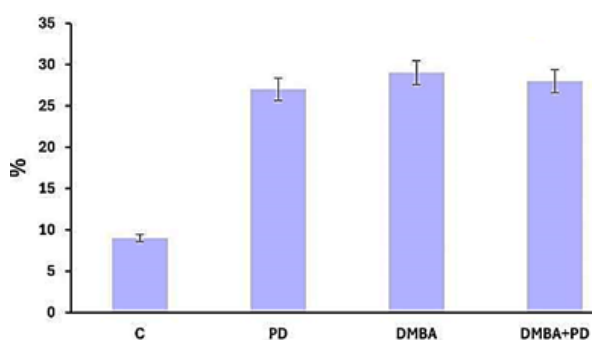


Furthermore, breast tissue of mice treated with PD173074 after tumor induction showed a significantly decreased immune response against KI-67 (Figure 4 C) with a significant decrease in tumor cell count and percentage of KI-67 incidence compared to untreated tumor group ( $p < 0.05$ ; Table 5).

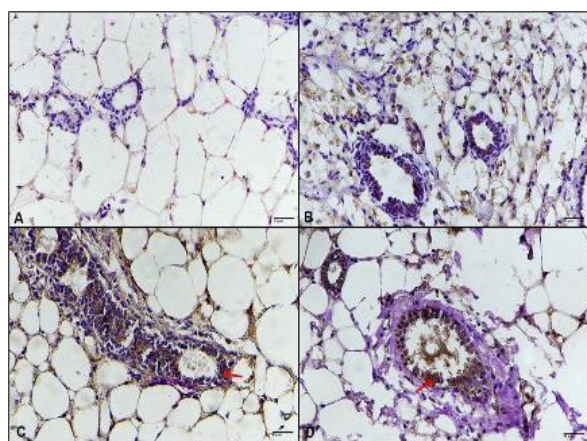
**Table 5:** Tumor cell count, absorbance, and percentage of KI-67 in mice breast

Group	Count	Absorbance (%)	Percentage (%)
Control	10±0	6±0.003	9.5±1.1
PD173074	11±0.4	9±0.1	10±2.2
DMBA	124±0.7 <sup>*a</sup>	20±0.01 <sup>*a</sup>	29±2.3 <sup>*a</sup>
DMBA+PD	56±0.53 <sup>*b</sup>	10±0.003 <sup>*b</sup>	24.4±4 <sup>*b</sup>

Mean ± SEM, <sup>\*a</sup> $p < 0.05$  vs control group, <sup>\*b</sup> $p < 0.05$  vs DMBA group



**Figure 3:** Bar graph of absorbance for M.tr. Showing high absorbance of groups treated with PD173074, DMBA and PD173074 following tumor induction compared to control



**Figure 4:** Photomicrographs of breast tissue stained immunohistochemically against KI-67. (A) un-treated control showing a weak immune response, (B) breast of mice treated with 50 mg/kg of PD173074 displaying weak immune response, (C) breast of mice treated with a single dose (50 mg/kg) of DMBA revealing intense immune response (red arrow), (D) breast of mice treated with 50 mg/kg of PD173074 after tumor induction indicating less immune response (ABC-400X)

## DISCUSSION

This present study used 7,12-dimethylbenz(a)anthracene (DMBA) an aromatic chemical carcinogen for mammary carcinoma induction. Many studies have used DMBA as a chemical tumor inducer, especially to induce mammary carcinoma in animals, it is hormone-dependent with ductal origin [10,11]. Induction of mammary carcinoma by DMBA leads to changes in female hormones estrogen and progesterone [12,13]. The present study reported that single injection of DMBA in the fat pad of the breast resulted in mammary carcinoma and a significant increase in female hormones, which ensured that the induced tumor was considered hormone-dependent. Additionally, the present study showed that treatment with PD173074 reduced raised estrogen and progesterone following induction of mammary carcinoma by DMBA. However, previous studies have revealed that DMBA injection increases response to oxidative stress by increasing MDA levels and decreasing GSH levels [14,15] which agrees with the findings of this present study leading to more lipid peroxidation process [16]. The present results reported that PD173074 treatment after carcinoma induction by DMBA resulted in significant MDA decrease and increase in GSH. Furthermore, DMBA injection significantly upregulated the pro-inflammatory cytokines (TNF- $\alpha$  and IL-6). Previous studies have shown that DMBA-induced mammary carcinoma consisted of tubular adenocarcinoma mixed with inflammation response due to the activation of pro-inflammatory cytokines leading to excessive release of TNF- $\alpha$  and IL-6 [17,18]. PD173074 caused significant decrease in pro-inflammatory cytokines, which may be due to reduction in carcinoma and inflammatory cells. DMBA-induced mammary carcinoma is pathologically described as tumor ribbons and nests of invasive ductal adenocarcinoma of relatively large atypical cells with different nuclei. Ductal adenocarcinoma surrounded by heavy desmoplastic reaction consists of depositions of collagenous fibers [19,15]. These findings harmonized with previous studies that DMBA injection in the fat pad of breast resulted in mammary carcinoma with pleomorphic atypical carcinoma cells formed nests that registered high scores according to Nottingham histopathological score in addition to heavy presence of desmoplastic stroma. Additionally, immunohistochemical reaction against KI-67 revealed strong immune response due to the ability of tumor cells to proliferate [19] which is in tandem with the result of this study. Also, DMBA-induced mammary carcinoma causes severe genetic mutations in cells of mammary glands

and ducts as DMBA metabolites form DNA adducts [20]. However, the present results pointed out that treatment with PD173074 following DMBA-induced mammary carcinoma resulted in lower presence of carcinoma cells in the breast and decreased pathological score but not the desmoplastic stroma reaction which appeared strong. Furthermore, results showed less immune reaction against KI-67 expression as evidence for decreasing carcinoma cell proliferation.

## CONCLUSION

PD173074 reduces mammary carcinoma cells, reduces female hormones, oxidative stress and cytokines that increase following DMBA induction, but did not affect the associated fibrosis. Additional studies would be required to validate the actual mechanisms of this drug action.

## DECLARATIONS

### Acknowledgement

The authors extend their appreciation to the research supporting project (RSP2024R174), King Saud University, Riyadh, Saudi Arabia.

### Funding

None provided.

### Ethical approval

Ethical approval was obtained from the Institutional Review Board (IRB), King Saud University, Riyadh, Saudi Arabia (no. KSU-SE-21-67).

### Availability of data and materials

The datasets used and/or analyzed during the current study are available from the corresponding author on reasonable request.

### Conflict of Interest

No conflict of interest associated with this work.

### Contribution of Authors

The authors declare that this work was done by the authors named in this article and all liabilities pertaining to claims relating to the content of this article will be borne by them.

## Open Access

This is an Open Access article that uses a funding model which does not charge readers or their institutions for access and distributed under the terms of the Creative Commons Attribution License (<http://creativecommons.org/licenses/by/4.0>) and the Budapest Open Access Initiative (<http://www.budapestopenaccessinitiative.org/read>), which permit unrestricted use, distribution, and reproduction in any medium, provided the original work is properly credited.

## REFERENCES

1. Mitra S, Dash R. Natural products for the management and prevention of breast cancer. *Evidence-based Complement Altern Med* 2018; 26: 1-24.
2. Shareef M, Ashraf M. Natural cures for breast cancer treatment: A review. *Saudi Pharm J* 2016; 24: 233-40.
3. Murphy C, Muscat A, Ashley D, Mukaro V, West L, Liao Y, Chisanga D, Shi W, Collins I, Baron-Hay S, et al. Tailored neoadjuvant epirubicin, cyclophosphamide and Nanoparticle Albumin-Bound paclitaxel for breast cancer: The phase II NEONAB trial-Clinical outcomes and molecular determinants of response. *PloS One* 2019; 14: e0210891.
4. Gottesman M, Fojo T, Bates S. Multidrug resistance in cancer: role of ATP-dependent transporters. *Nat Rev Cancer* 2002; 2: 48-58.
5. Balasubramanian B, Yacqub-Usman K, Venkatraman S, Myint K, Juengsamarn J, Sarkhampee P, Lertsawatvicha N, Sripa J, Kuakpaetoon T, Suriyonplengsaeng C, et al. Targeting FGFRs Using PD173074 as a Novel Therapeutic Strategy in Cholangiocarcinoma. *Cancers (Basel)* 2023; 15: 2528.
6. Ye T, Wei X, Yin T, Xia Y, Li D, Shao B, Song X, He S, Luo M, Gao X, et al. Inhibition of FGFR signaling by PD173074 improves antitumor immunity and impairs breast cancer metastasis. *Breast Cancer Res Treat* 2014; 143: 435-446.
7. Takahashi H, Oshi M, Asaoka M, Yan L, Endo I, Takabe K. Molecular biological features of Nottingham histological grade 3 breast cancers. *Ann Surg Oncol* 2020; 27: 4475-4485.
8. National Research Council. *Guide for the care and use of laboratory animals*, National Academies Press. Washington, DC: 2010.
9. Feng M, Feng C, Yu Z, Fu Q, Ma Z, Wang F, Wang F, Yu L. Histopathological alterations during breast carcinogenesis in a rat model induced by 7,12-Dimethylbenz (a) anthracene and estrogen-progestogen combinations. *Int J Clin Exp Med* 2015; 8: 346-357.
10. Hamza A, Khasawneh M, Elwy H, Hassanin S, Elhabal S, Fawzi N. *Salvadora persica* attenuates DMBA-induced mammary cancer through downregulation oxidative stress, estrogen receptor expression and proliferation

- and augmenting apoptosis. *Biomed Pharmacother* 2022; 147: 112666.
11. Hamdy S, Latif A, Drees E, Soliman S. Prevention of rat breast cancer by genistein and selenium. *Toxicol Ind Health* 2011; 28: 746–757.
  12. Al-Anazy I, Al-Dahmash B, El-Nagar D, Ibrahim K, Al-Tamimi J, Rady A, Khan M. Hyper-ovulation, endometriosis, and hyperplasia associated with tamoxifen exposure in Swiss albino mice. *J King Saud Univ - Sci* 2020; 32: 3026–3033.
  13. Muqbil I, Fatima S, Azmi A, Alsharidah A, Khan S, Aljaser F, Banu N. Restraint stress abates the antioxidant potential of melatonin on dimethyl benz (a) anthracene (DMBA) induced carcinogenesis. *Med Oncol* 2020; 37: 96.
  14. Alanazy I, Aldahmash B, El-nagar DM, Ibrahim KE, Rady A, Khan M. Melatonin abrogates liver, ovarian, and uterine toxicities induced by tamoxifen in a breast cancer mouse model. *Indian J Exp Biol* 2021; 59: 33–43.
  15. Batcioglu K, Uyumlu A, Satilmis B, Yildirim B, Yucel N, Demirtas H, Onkal R, Guzel R, Djamgoz M. Oxidative stress in the in vivo DMBA rat model of breast cancer: suppression by a voltage-gated sodium channel inhibitor (RS100642). *Basic Clin Pharmacol Toxicol* 2012; 111: 137-141.
  16. Abdelmeguid N, Khalil M, Badr N, Alkhuriji A, El-Gerbed M, Sultan A. Ameliorative effects of colostrum against DMBA hepatotoxicity in rats. *Saudi J Biol Sci* 2021; 28: 2254–2266.
  17. Youssef S, Ibrahim N, El-Sonbaty S, El-Din Ezz M. Rutin Suppresses DMBA carcinogenesis in the breast through modulating IL-6/NF- $\kappa$ B, SRC1/HSP90 and ER- $\alpha$ . *Nat Prod Commun* 2022; 17: 1934578X221118213.
  18. Hendi A, El-Nagar D, Awad M, Ortashi K, Alnamlah R, Merghani N. Green nanogold activity in experimental breast carcinoma in vivo. *Biosci Rep* 2020; 40: 1–12.
  19. Gao J, Mitchell L, Lauer F, Burchiel S. p53 and ATM/ATR regulate 7,12-dimethylbenz(a)anthracene-induced immunosuppression. *Mol Pharmacol* 2008; 73: 137–146.
  20. Saleh A, Hassan N, Ismail M, El-Sayed WM. New fluorobenzamidine exerts antitumor activity against breast cancer in mice via pro-apoptotic activity. *Discov Oncol* 2022; 13: 88.