Tropical Journal of Pharmaceutical Research November 2026; 25 (11): 1523-1529
**ISSN:** 1596-5996 (print); 1596-9827 (electronic)

Available online at http://www.tjpr.org
**https://dx.doi.org/10.4314/tjpr.v25i11.5**

## Original Research Article

# The role of catechin and *Ginkgo biloba* against oxidative stress induced by high doses of paracetamol in male rats

**Zainab A Nasser*, Ausama Ayob Jaccob**
*Department of Pharmacology and Toxicology, College of Pharmacy, University of Basrah, Basrah, Iraq*

**For correspondence:* ***Email:*** *zainab.nasserr@uobasrah.edu.iq*

*Sent for review: 5 August 2026* *Revised accepted: 11 November 2026*

## *Abstract*

***Purpose:*** *To investigate the antioxidant and protective effects of catechin and Ginkgo biloba against N-acetyl-p-aminophenol (APAP)-induced liver injury in male Wistar rats.*
***Methods:*** *A total of 42 male rats were randomly assigned to 6 groups (n = 7). Group 1 was the control, group 2 received APAP only, group 3 received N-acetylcysteine (NAC) + APAP, group 4 received catechin + APAP, group 5 received G. biloba + APAP, and group 6 received catechin + Ginkgo + APAP for 14 days, with a single paracetamol overdose on day 13. On day 15, liver tissues were analyzed for reduced glutathione (GSH), superoxide dismutase (SOD), and catalase levels, and histoarchitecture.*
***Results:*** *Treatment with APAP significantly reduced GSH, SOD and catalase, with significant liver damage compared to controls ($p < 0.05$). Furthermore, pre-treatments with N-acetylcysteine (NAC), catechin, G. biloba, and combination significantly increased GSH, SOD, and catalase levels compared to group 2 and controls ($p < 0.05$).*
***Conclusion:*** *Combination of catechin and Ginkgo biloba significantly increases GSH, SOD, and catalase levels compared to controls and single therapy.*

***Keywords:*** *Catechin, Ginkgo biloba, Hepatotoxicity, Oxidative stress, Paracetamol*

**This is an Open Access article that uses a funding model which does not charge readers or their institutions for access and distributed under the terms of the Creative Commons Attribution License (http://creativecommons.org/licenses/by/4.0) and the Budapest Open Access Initiative (http://www.budapestopenaccessinitiative.org/read), which permit unrestricted use, distribution, and reproduction in any medium, provided the original work is properly credited.**

**Tropical Journal of Pharmaceutical Research is indexed by Scopus, Chemical Abstracts, Embase, Index Copernicus, EBSCO, African Index Medicus, JournalSeek, Directory of Open Access Journals (DOAJ), African Journal Online, Bioline International, Open-J-Gate and Pharmacy Abstracts**

## INTRODUCTION

The liver is a vital organ serving as a central hub for carbohydrate, protein, and lipid metabolism, while simultaneously facilitating waste excretion. The key defensive function relies on biotransformation mechanisms to detoxify and excrete both endogenous metabolic waste and foreign substances (xenobiotics) into bile. Impairment of this intricate detoxification system renders the liver highly susceptible to injury, and a primary target for drug-induced liver injury (DILI) [1]. Acetaminophen, also termed N-acetyl-p-aminophenol (APAP), is the leading cause of DILI. It exhibits analgesic and antipyretic activity at therapeutic doses; however, excessive doses cause acute liver failure (ALF) [2]. It undergoes metabolism through sulfation and glucuronidation pathways to produce unreactive metabolites. However, bioactivation by cytochrome P450 enzyme system results in the formation of reactive electrophilic intermediate N-acetyl-p-benzoquinone imine (NAPQI), which causes zone 3 hepatic necrosis. Under physiological conditions, NAPQI is detoxified by conjugation with glutathione. Excess NAPQI formation depletes hepatic glutathione and oxidizes cellular macromolecules. When the rate of synthesis exceeds clearance rate, cell death occurs. Lipid peroxidation and free radical production further

*© 2026 The authors. This work is licensed under the Creative Commons Attribution 4.0 International License*

enhance this damage, while protective mechanisms are closely related to antioxidant activity [3].

Hepatocytes employ compensatory mechanisms to combat reactive oxygen species (ROS), and upregulate antioxidant enzymes such as superoxide dismutase (SOD), catalase, GSH reductase (GR), and glutathione peroxidase (GSHPx). The enzymatic antioxidant system directly or sequentially inhibits ROS to prevent toxicity. Oxidative injury is the imbalance between oxidative stress and antioxidant defense and is a key factor in several diseases such as diabetes, atherosclerosis, cancer, and liver cirrhosis [4]. N-acetylcysteine (NAC) is the antidote approved by the U.S. Food and Drug Administration to mitigate APAP-induced hepatotoxicity. However, its broad clinical utility is severely limited by a narrow therapeutic time window, notable adverse side effects, and emerging drug resistance [5]. Therefore, there is an urgent need for newer approaches to improve treatment efficacy. Catechin is a polyphenol of the flavonoid family. Its protective effects against various hepatic diseases are mainly due to its potent antioxidant and radical scavenging capabilities [6]. *Ginkgo biloba* (*G. biloba*) is an ancient plant species known to provide broad physiological health benefits to living organisms. The plant possesses significant hepatoprotective activity and antioxidant defense properties, due to the presence of terpenoids and glycosides abundant in the leaf extract. Recent studies showed that polysaccharides isolated from *G. biloba* have various therapeutic activities such as antioxidant, anti-inflammatory, anti-tumor, hepatoprotective, and antidepressant properties [7]. This study evaluated and compared the hepatoprotective potentials of catechin and *Ginkgo biloba* in paracetamol-induced acute liver injury model. Although both natural compounds have been independently investigated in previous research, the novelty of this study lies in integrating tissue antioxidant profiling with comprehensive histopathological evaluation and multivariate statistical methods to systemically assess the protective mechanisms under standardized experimental conditions.

## METHODS

### Animals

A total of 42 healthy male Wistar albino rats (aged 4 – 6 weeks, 100 - 150 g) were randomly and equally assigned to 6 groups (n = 7). The animals were kept in polypropylene cages to acclimatize for 2 weeks under standard conditions (21 ± 3°C, 12 h light/dark cycle) with unrestricted access to feed and water *ad libitum*. The study was conducted at the Animal house of the College of Pharmacy, University of Basrah, Iraq. Ethical approval was obtained from the Institutional Animal Care and Use Committee (IACUC) of the College of Pharmacy, University of Basrah, Iraq (approval no: EC-109).

### Design

A total of 42 healthy male Wistar albino rats (aged 4 – 6 weeks, 100 - 150 g) were randomly and equally assigned to 6 groups (n = 7). Group 1 was the control and received 0.5 % carboxymethyl cellulose (CMC), group 2 (negative control) received APAP only, groups 3, 4, 5 and 6 were induced with APAP and received N-acetylcysteine (NAC; Quantum Nutrition Labs, USA; 100 mg/kg/day), received catechin (NOW Health Group, USA; 100 mg/kg/day), *G. biloba* (NutraLeague, UK; 100 mg/kg/day), and catechin (100 mg/kg/day) + Ginkgo (100 mg/kg/day) respectively for 14 days. The single APAP overdose (2 g/kg) was administered on day 13 [8].

### Sample collection

On day 15, 48 h following APAP overdose, the animals were sacrificed under chloroform anesthesia. Liver tissues were collected and divided into two portions. One portion was fixed in 10 % formalin for histopathological examination. The other was rinsed with PBS (pH 7.4), homogenized at a 1:10 (w/v) ratio, and centrifuged at 8000 rpm for 10 min at 4 °C. The resulting supernatant was stored at −80 °C for antioxidant analysis.

### Biochemical analysis

The supernatant of liver tissues were assayed for Hepatic GSH (Cat No: E-BC-1170), SOD (Cat No: BC-0170), and catalase (Cat No: BC-0200) using commercial Solarbio kits (Life Sciences, Beijing) following manufacturer's instructions [9].

### Histopathological Examination

Formalin-fixed liver tissues were dehydrated through graded ethanol, cleared with xylene, embedded in paraffin, and sectioned at 4–5 µm using a rotary microtome. Sections were stained with hematoxylin and eosin (HE) and examined at x400 magnification using a Leica light microscope (Leica Microsystems, Germany) for histopathological changes [10].

### Statistical analysis

Data were analyzed using GraphPad Prism version 8 (GraphPad Software, USA). Measurement data were expressed as mean ± standard deviation (SD), analyzed using one-way analysis of variance (ANOVA), and compared with Tukey's post hoc test for between-group comparisons. $P < 0.05$ was considered statistically significant.

## RESULTS

### Levels of hepatic glutathione (GSH)

Group 2 showed significantly lower GSH compared to control, indicating severe APAP-mediated oxidative stress ($p < 0.05$).

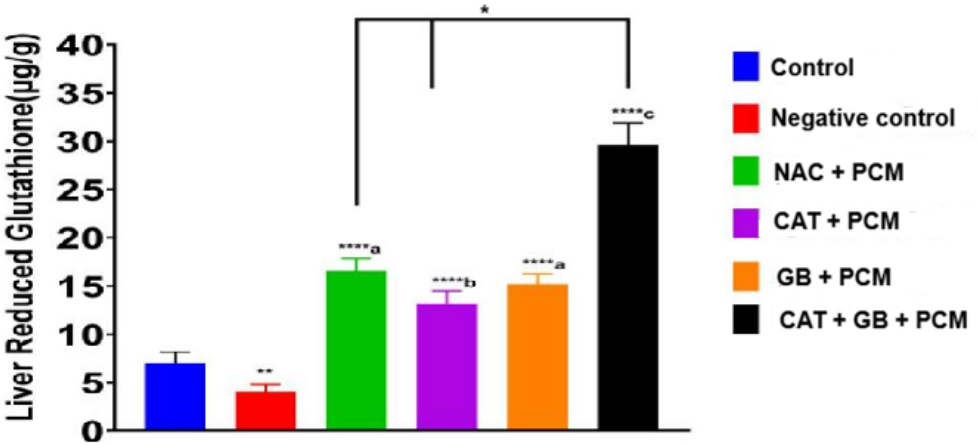


**Figure 1:** Liver GSH levels in paracetamol-induced liver damage. *$P < 0.05$ compared to control groups, **$p < 0.001$ compared to control, ****$p < 0.0001$ compared to control. $^{abc}P < 0.05$ between treated groups. Reduced glutathione (GSH), paracetamol (PCM), N-acetylcysteine (NAC), Catechin (CAT), *Ginkgo biloba* (GB)

Pre-treatment with NAC, catechin and *G. biloba* significantly increased and restored GSH levels compared to group 2 ($p < 0.0001$). Also, groups 3 and 5 showed significantly higher GSH levels compared to group 4 ($p < 0.05$). Furthermore, combination therapy of catechin and *G. biloba* significantly increased hepatic GSH levels compared to other groups ($p < 0.05$; Figure 1).

### Levels of hepatic superoxide dismutase (SOD)

Group 2 showed a significant decrease in SOD activity compared to control group ($p < 0.05$). Treatment with NAC, catechin, and *G. biloba* significantly increased SOD activity compared to group 2 ($p < 0.0001$; Figure 2).

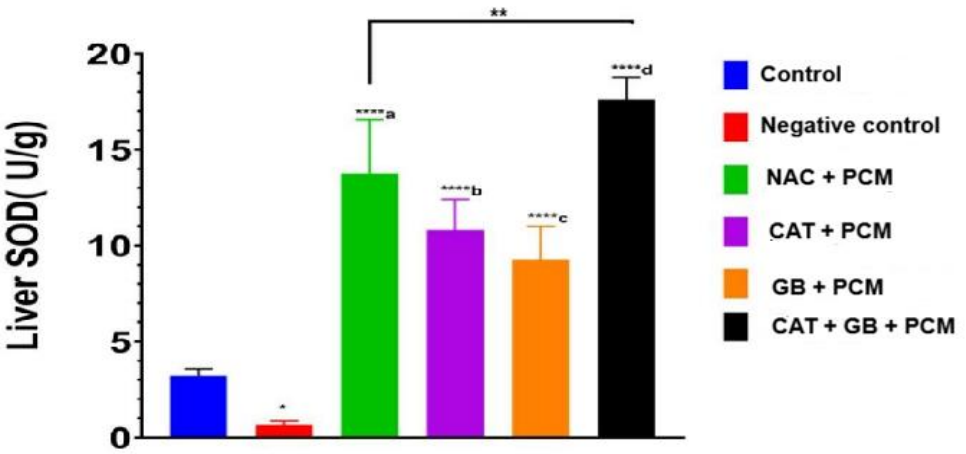


**Figure 2:** Liver SOD levels. *$P < 0.05$ compared to control, ****$p < 0.0001$ compared to control. $^{abcbd}P < 0.05$ between treated groups. Reduced glutathione (GSH), paracetamol (PCM), N-acetylcysteine (NAC), Catechin (CAT), *Ginkgo biloba* (GB)

Furthermore, treatment with NAC, Catechin, and *G. biloba* significantly increased SOD levels compared to control groups ($p < 0.05$). Combination therapy significantly increased SOD levels compared to single therapy and control groups ($p < 0.05$; Figure 2).

**Hepatic catalase levels**

Group 2 showed significantly lower catalase levels compared to control ($p < 0.0001$). However, administration of NAC, catechin, G. biloba, and catechin + *G. biloba* significantly restored catalase levels compared to negative control group ($p < 0.0001$). Furthermore, combination therapy significantly increased catalase levels compared to individual drug and control groups ($p < 0.05$; Figure 3).

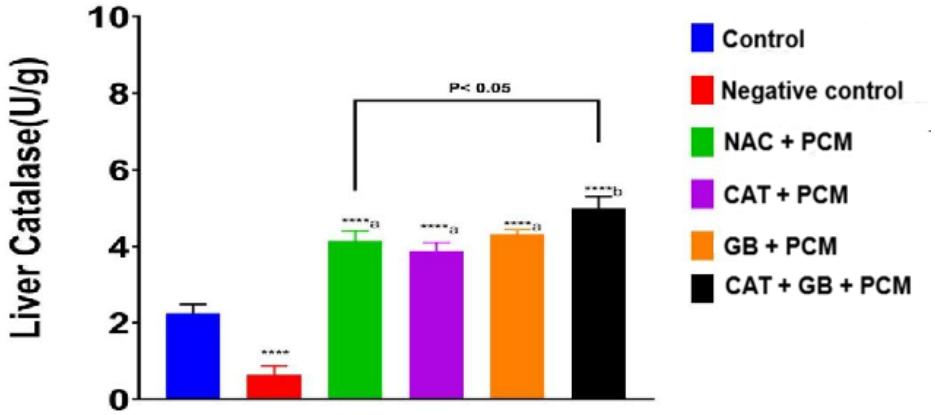


**Figure 3:** Hepatic catalase levels ****$P < 0.0001$ compared to control group. $^{ab}P < 0.05$ compared to between treated groups. Reduced glutathione (GSH), paracetamol (PCM), N-acetylcysteine (NAC), Catechin (CAT), *Ginkgo biloba* (GB)

**Histological study**

Control group showed normal histoarchitecture characterized by intact hepatocytes, normal central veins, and radiating sinusoids (Figure 4 A). Group 2 showed significant hepatic injury, evidenced by widespread centrilobular necrosis, loss of cellular and nuclear details, cytoplasmic vacuolation, severe sinusoidal congestion, and inflammatory cell infiltration (Figure 4 B). Group 3 showed significant improvement in hepatic architecture, characterized by preserved hepatic cords, mild residual vascular congestion, and focal inflammatory infiltration (Figure 4 C). Group 4 showed moderate protection, with relatively preserved hepatocytes, localized areas of necrosis and inflammatory cell infiltration (Figure 4 D). Greater protection was observed in group 5 characterized by preserved structural integrity, intact central vein, well-arranged hepatocyte cords, and only mild local perivascular inflammatory cell aggregation (Figure 4 E). Furthermore, combination regimen demonstrated the greatest degree of hepatic preservation, with architecture approaching that of control group (absence of APAP-induced parenchymal necrosis, cytoplasmic vacuolation, and severe congestion with only minimal inflammatory cell presence adjacent to the central vein; Figure 4 F), indicating a strong synergistic hepatoprotective effect of the combined treatment against APAP-induced hepatic injury.

**DISCUSSION**

Oxidative stress is an important mechanism in paracetamol toxicity, which represents a state of imbalance between oxidant species and antioxidant capacity. When phase II enzymes saturate after an APAP overdose, excess NAPQI depletes GSH, causing covalent binding to cellular proteins, especially mitochondrial proteins. This leads to oxidative outburst and mitochondrial dysfunction. Increased superoxide formation leads to hydrogen peroxide formation and peroxidation.

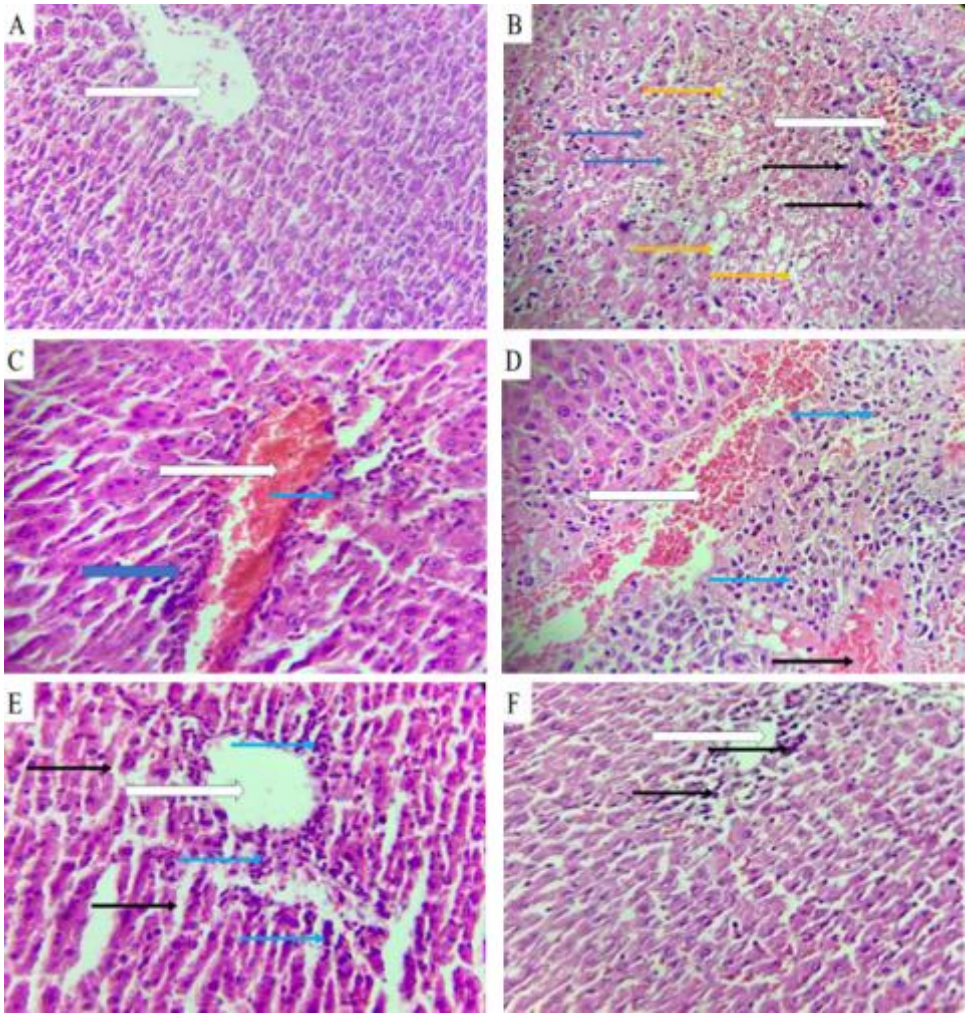


**Figure 4:** Light micrograph of the rat liver sections stained with H and E (X 400). A (Control group) showed normal hepatic cytoarchitecture with an intact central vein (white arrow) and well-organized radiating cords of healthy hepatocytes. B (APAP-overdosed group): Revealing severe central vein congestion (white arrow), steatosis lipid vacuoles within hepatocytes and degeneration (orange arrow), area of necrosis (black arrow), accompanied by inflammatory cell infiltration (blue arrows). C (NAC-treated group) showed restored hepatic cords with persistent central vein congestion (white arrow) and perivascular inflammatory cell infiltration (blue arrows). D (Catechin-treated group) showed preserved hepatocytes with central sinusoidal congestion (white arrow), inflammatory cell infiltration (blue arrows), and focal necrotic changes (black arrows). E (Ginkgo biloba-treated group) showed intact central vein (white arrow), well-arranged hepatocytes cords (black arrow), and mild focal inflammatory cell infiltration (blue arrow). F (Combination-treated group) showed near-normal liver cytoarchitecture with an intact central vein (white arrow) and minimal localized inflammatory cell presence (black arrow)

Superoxide dismutase (SOD) is the primary antioxidant against ROS, especially superoxide radicals [11]. Hepatic GSH levels and activities of SOD and catalase were lower in group 2 compared to control, suggesting that prooxidant-to-antioxidant ratio shifted toward prooxidants. Pretreatment with NAC significantly increased hepatic GSH, SOD, and catalase levels compared to catechin or *G. biloba* alone. This is because NAC is a GSH precursor and can prevent tissue damage by increasing GSH, scavenging ROS, and inhibiting inflammatory cytokine production [12]. Pre-treatment with combination of catechin and *G. biloba* increased GSH levels and activities of SOD and catalase. This is consistent with previous studies that catechin attenuates oxidative stress by increasing antioxidant defenses and enzyme activity, including SOD and catalase. *G. biloba* contains flavonoids having antioxidant properties which protect the liver from paracetamol damage by scavenging reactive species, donating hydrogen to break radical reactions, and decreasing lipid peroxidation [13].

Histopathological results further supported the biochemical results and showed considerable and severe hepatic injury in the APAP-treated group. High doses of paracetamol were previously reported to induce significant structural changes in hepatic parenchyma, ultimately leading to acute liver failure [14]. Furthermore, these local tissue alterations are mainly the result of accumulation of reactive toxic metabolite (N-acetyl-p-benzoquinone imine (NAPQI)) secondary to hepatic glutathione (GSH) depletion [15,16]. Excess NAPQI readily conjugates with intracellular cellular proteins and macromolecules, leading to mitochondrial energy failure, severe oxidative damage, and membrane lipid peroxidation.

This mechanism initiates programmed cell death (apoptosis), resulting in hepatic necrosis [17]. Furthermore, even though there were moderate anti-inflammatory effects on livers treated with catechin, these did not inhibit the presence of necrotic foci in several parts of the livers, showing that it failed to stabilize the mitochondrial membrane from severe injuries due to NAPQI. In contrast, livers treated with G. biloba extract showed more preserved hepatic structure, with only mild foci of inflammation, highlighting its potent mitochondrial membrane protection and antiapoptotic activity [18].

## CONCLUSION

Combination of catechin and *Ginkgo biloba* significantly increased GSH, SOD, and catalase levels, maintained liver cytoarchitecture, and inhibited development of centrilobular necrosis. This is a promising treatment approach for the prevention or attenuation of toxic drug-induced liver impairment.

## DECLARATIONS

### Acknowledgment

The authors are thankful to the Deanery and staff of the College of Pharmacy, University of Basrah, for providing the required laboratory facilities, animal housing, and technical support to finish this research project.

### Funding

This research was not funded by any specific grant from any funding body in the public, private, or not-for-profit sectors.

### Conflicts of interest

The authors declare no conflict of interest.

### Use of Artificial intelligence/Large language models

The authors confirm that AI-based tools were used solely for language editing and manuscript polishing purposes (e.g., grammar, phrasing, and clarity). No AI tools were used to generate content, interpret data, or influence study design, results, or conclusions. All intellectual contributions, study analyses, and interpretations reported in the manuscript are the original work of the authors.

### Availability of data and materials

The datasets used and/or analyzed during the current study are available from the corresponding author upon reasonable request.

### Contribution of authors

We declare that this work was done by the author(s) named in this article, and all liabilities pertaining to claims relating to the content of this article will be borne by the authors.

## REFERENCES

1. *Andrade RJ, Chalasani N, Bjornsson ES, Suzuki A, Kullak-Ublick GA, Watkins PB, et al. Drug-induced liver injury. Nat Rev Dis Primers 2019; 5(1): 58. doi: 10.1038/s41572-019-0105-0.*
2. *Yoon E, Babar A, Choudhary M, Kutner M, Pyrsopoulos N. Acetaminophen-induced hepatotoxicity: a comprehensive update. J Clin Transl Hepatol 2016; 4(2): 131-42. doi: 10.14218/JCTH.2015.00052.*
3. *McGill MR, Jaeschke H. Metabolism and disposition of acetaminophen: recent advances in relation to hepatotoxicity and diagnosis. Pharm Res 2013; 30(9): 2174-2187. doi: 10.1007/s11095-013-1007-6.*
4. *Allameh A, Niayesh-Mehr R, Aliarab A, Sebastiani G, Pantopoulos K. Oxidative stress in liver pathophysiology and disease. Antioxidants (Basel) 2023; 12(9): 1653. doi: 10.3390/antiox12091653.*
5. *Ramachandran A, Akakpo JY, Curry SC, Rumack BH, Jaeschke H. Clinically relevant therapeutic approaches against acetaminophen hepatotoxicity and acute liver failure. Biochem Pharmacol 2024; 228: 116056. doi: 10.1016/j.bcp.2024.116056.*
6. *Kim JM, Heo HJ. The roles of catechins in regulation of systemic inflammation. Food Sci Biotechnol 2022; 31(8): 957-970. doi: 10.1007/s10068-022-01069-0.*
7. *Noor-E-Tabassum, Das R, Lami MS, Chakraborty AJ, Mitra S, Tallei TE et al. Ginkgo biloba: a treasure of functional phytochemicals with multimedicinal applications. Evid Based Complement Alternat Med 2022; 2022: 8288818. doi: 10.1155/2022/8288818.*

8. Samuhasaneeto S, Kajornvuthidej S. Negative effects of Aloe vera gel on paracetamol-induced liver injury in rats. ScienceAsia 2014; 40(1): 42-47. doi: 10.2306/scienceasia1513-1874.2014.40.042.
9. Solarbio kit protocols Manufacturer's instructions; Cat Nos E-BC-1170, BC-0170, BC-0200.
10. Feldman AT, Wolfe D. Tissue processing and hematoxylin and eosin staining. Methods Mol Biol 2014; 1180: 31-43. doi: 10.1007/978-1-4939-1050-2_3.
11. Ramachandran A, Jaeschke H. Oxidant stress and acetaminophen hepatotoxicity: mechanism-based drug development. Antioxid Redox Signal 2021; 35(9): 718-733. doi: 10.1089/ars.2021.0102.
12. Tenorio MCDS, Graciliano NG, Moura FA, Oliveira ACM, Goulart MOF. N-Acetylcysteine (NAC): impacts on human health. Antioxidants (Basel) 2021; 10(6): 967. doi: 10.3390/antiox10060967.
13. Yao M, Liu L, Hao Z, Shen J, Dai C. A narrative review of ginkgo biloba extract: biological function, molecular mechanisms, and applications in animal production. Antioxidants (Basel) 2026; 15(2): 251. doi: 10.3390/antiox15020251.
14. Muhammad-Azam F, Nur-Fazila SH, Ain-Fatin R, Mustapha Noordin M, Yimer N. Histopathological changes of acetaminophen-induced liver injury and subsequent liver regeneration in BALB/C and ICR mice. Vet World 2019; 12(11): 1682-1688. doi: 10.14202/vetworld.2019.1682-1688.
15. Ahmed HM, Shehata HH, El-Saeed GSM, Gabal HHA, El-Daly SM. Paracetamol overdose induces acute liver injury accompanied by oxidative stress and inflammation. Egypt J Chem 2023; 66(3): 399-408. doi: 10.21608/EJCHEM.2022.140587.6153.
16. Jaeschke H, Ramachandran A. Acetaminophen hepatotoxicity: paradigm for understanding mechanisms of drug-induced liver injury. Annu Rev Pathol 2024; 19(3): 453-478. doi: 10.1146/annurev-pathmechdis-051122-094016.
17. Luo G, Huang L, Zhang Z. The molecular mechanisms of acetaminophen-induced hepatotoxicity and its potential therapeutic targets. Exp Biol Med (Maywood) 2023; 248(5): 412-424. doi: 10.1177/15353702221147563.
18. Wang Y, Wang R, Wang Y, Peng R, Wu Y, Yuan Y. Ginkgo biloba extract mitigates liver fibrosis and apoptosis by regulating p38 MAPK, NF-κB/IκBα, and Bcl-2/Bax signaling. Drug Des Devel Ther 2015; 9: 6303-6317. doi: 10.2147/DDDT.S93732.